

CASE REPORT

CLINICAL AND RADIOLOGICAL APPROACH OF POSTERIOR REVERSIBLE ENCEPHALOPATHY SYNDROME ON ECLAMPSIA

Fakhrurrazy, Herly Maulida Surdhawati**

*Department of Neurology Faculty of Medicine Lambung Mangkurat University, Banjarmasin, Indonesia

pISSN : 2407-6724 • eISSN : 2442-5001 • <http://dx.doi.org/10.21776/ub.mnj.2017.003.02.6> • MNJ.2017;3(2):88-93
• Received 28 November 2016 • Reviewed 16 June 2017 • Accepted 5 July 2017

ABSTRACT

Posterior reversible encephalopathy syndrome (PRES) is rare clinico-neuroradiologic condition and not commonly reported in the literature, a recently recognized syndrome characterized clinically by headache, confusion, seizure and visual loss associated, with imaging findings of bilateral cortical and subcortical oedema, predominantly posterior cerebral lesions (mainly occipito-parietal). Posterior reversible encephalopathy syndrome is an uncommon complication of severe preeclampsia/ eclampsia. The objective of this study is to report PRES case on eclampsia with clinical and radiological approach. We report a case of woman, 34 years old woman, with chief complaint tonic clonic general seizure and sudden headache previously. This patient had pregnancy 8 gestational month and had pregnancy termination with cesarean section recently. Patient had loss of consciousness, vision disturbance, and weakness of right extremities, all this symptom become well during treatment. The result of laboratory examination was HELLP syndrome (haemolysis, elevated liver enzymes and low-platelets). Head CT scan showed hypodense lesion in left parietooccipital region and MRI on T2W and T2FLAIR ADC MAPS found hyperintens lesion in right and left parietooccipital. Then it can be concluded that it have been reported cases of eclampsia with PRES with symptom of headache, seizure, mental status disturbance, visual disturbances. The pathological association between PRES and HELLP syndrome in a patient with eclampsia is poorly described.

Keywords: Posterior reversible encephalopathy syndrome, clinical, radiological, eclampsia

Correspondence: herlymaulida@yahoo.co.id

INTRODUCTION

Posterior reversible encephalopathy syndrome (PRES) is a syndrome that clinically present with headache, confuse, seizure, and visual loss. Since the first description in 1996, PRES has been reported to be formed in central clinical condition, weither with increased blood pressure or any particular drug consumption.^{1,2}

Imaging modality showed symmetrical lesion usually at substantia alba and posterior grisea. A proper hypertension treatment or not using any particular drug becomes important in order to assure reversibility of the deficit. This following case report was reported about eclampsia case that develop into PRES.³

The pathophysiology of this disease is not fully understood yet. It is happen to be multifactorial with the result in vasogenic edema of brain tissue, combination of vasogenic-sitotoxic edema.⁴

CASE REPORT

A 34-year-old woman came with a general tonic clonic seizure as the main complaint. The patient had a sudden severe headache before the seizure, the headache was felt around the head. She was on eight month pregnancy at that time and it was her fifth pregnancy. At the day three of care her pregnancy were terminated by sectio caesarea. At the day four of care the patient was apathetic and had of right lateralization, and at the day five she was compos mentis and weakness of the right limb, burred vision, and the patient could only see a hand motion from a half meter in both of eyes. After a few days, the viusal acuity and the right limb weakness was better.

The physical examination at the first time came to hospital was somnolence (induced by diazepam), blood pressure 120/80 mmHg, axillary temperature 36.5 °C, heart rate 106/ minute, respiratory rate 20/ minute , height 155 cm, and weight 65 kg. Thorax and abdominal examination was normal, lower extremity edema, and another systemic examination was normal. Neurological examination shown visual acuity OD and OS 2/60, dexter hemiparesis, right babinski reflex was found.

Laboratorium results was increasing of transaminase liver enzyme, SGOT 396 U/L (normal: 11-39 U/L) and SGPT 376 U/L (normal : 10-37 U/L);

urea 64 mg/dL, creatinine 0.59 mg/dL, total cholesterol 271, triglycerides 371, albumin 2.3, hematokrit 26.1%, hemoglobin 8.7 g/dL (12.3-15.3 g/dL), leukosit 14.09/mm³ (4.000-11.000 mm³) and platelet 21.000 /mm³ (150.000-450.000 mm³). A routine urine result was proteinuria. These findings supported HELLP syndrome.

Head CT scan results with and without contrast showed hypodens lesion at parietooccipital sinister with perifocal edema and soft enhancement with the contrast. Cranial MRI T1W with and without contrast, T2W and T2FLAIR ADC MAPPS, showedl hyperintens lesion at T2W and T2FLAIR ADC MAPS at right and left parietooccipital unclear at T1W and no presenting of enhancement post contrast (image below).

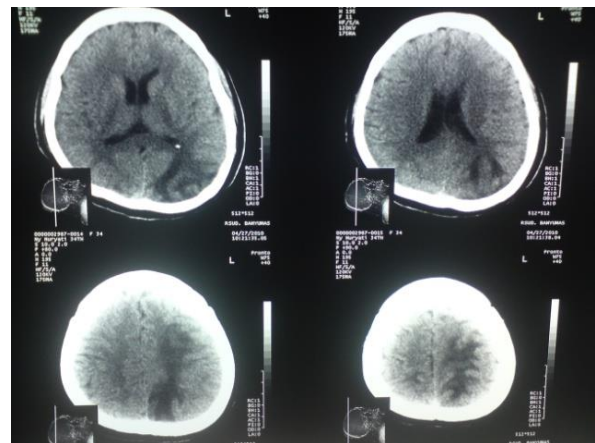


Figure 1. Axial Head CT scan without contrast

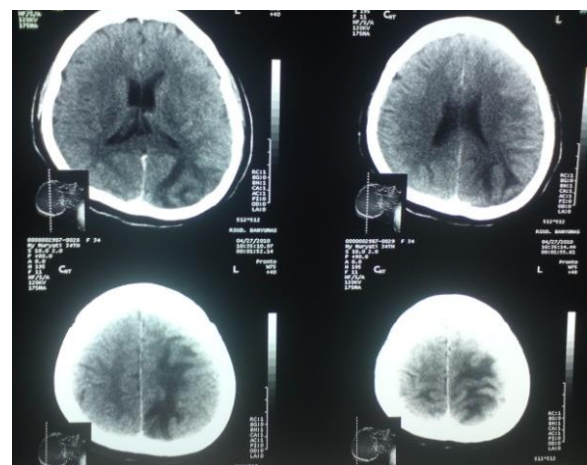


Figure 2. Axial Head CT scan with contrast

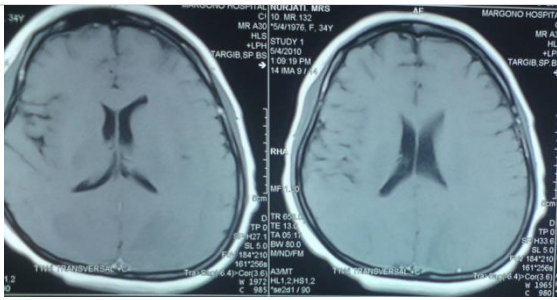


Figure 3. Transversal Head MRI T1W1

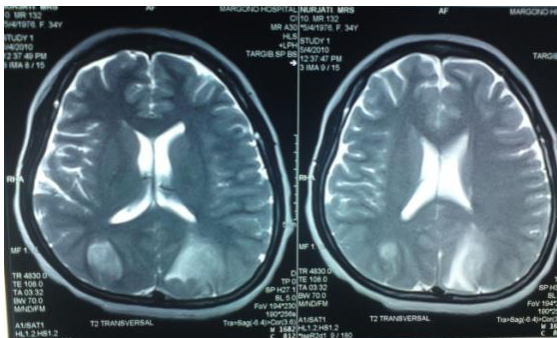


Figure 4. Transversal Head MRI T2

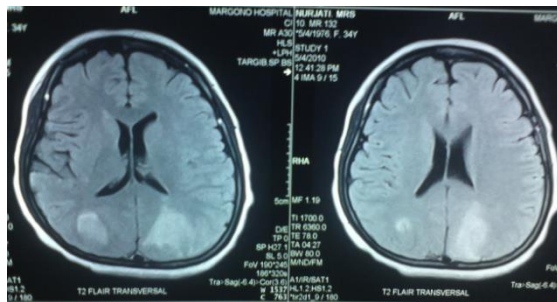

Figure 5. Transversal Head MRI T2 FLAIR

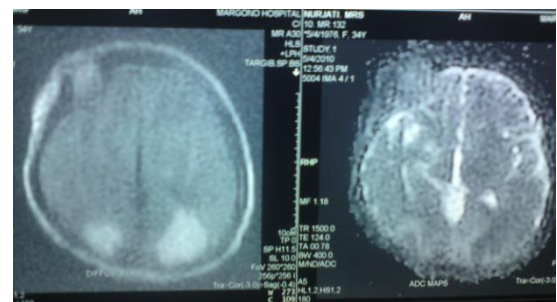


Figure 6. Head MRI ADC MAPS

DISCUSSION

Posterior reversible encephalopathy syndrome (PRES), as the name suggests, is a constellation of symptoms caused by reversible ischemia most commonly of the posterior cerebral vasculature, thus affecting the parietal-occipital region⁵.

Posterior reversible encephalopathy syndrome firstly explained by Hinchey et al. at 1996 and well known as reversible posterior leucoencephalopathy syndrome too, the clinical definition is an association of neurological signs and radiological disorder of occipital alba substantia, usually bilateral, marked by cerebral edema with hipodens sign at CT scan and hiperdens sign at T2 weighted by MRI imaging. This syndrome occurs on the patient that has encephalopathy hypertension, renal failure, immunosuppression, and postpartum eclampsia⁴.

Seizures are cited as the most common manifestation of PRES, occurring in up to 90% of reported cases. Seizure activity on the EEG was defined as continuous or recurrent rhythmic focal or generalized spikes; sharp waves; spike waves; or rhythmic waves changing in amplitude, frequency, and/ or spatial distribution. Visual disturbances can range from complaints of blurred vision to cortical blindness. Symptoms develop over hours and can persist for weeks, depending on the severity and the latency in initiating proper treatment. Acute hypertension is also associated with the majority of PRES cases, but is not necessary for the diagnosis, and the degree of elevation varies.^{6,7}

Eclampsia is a serious complication that occurs at 5% of pregnancy and causes 10% of gestational-related mortality. Clinical eclampsia is defined as seizure or coma that related with gestational and induced by hypertension. The patient is usually followed by headache, change of mental status, cortical blindness, and seizure⁸. Eclampsia and other pathological can cause PRES. In addition, the fluctuation of blood pressure can causes various degree of vasospasm and vasodilatation. At the end, cerebral autoregulation disorder causes disruption of blood brain barrier at posterior circulation.^{9,10}

The imaging of patient with eclampsia is identic with hypertension encephalopathy. Ct scan shows posterior transitorik area shows patchy low attenuation. MRI is better than CT on encephalopathy eclampsia imaging. The lesion is marked by a low intensity sign on T1-weighted and high intensity sign on T2-weighted image at posterior cortex and substantia alba subcortical.¹¹

The mechanism the posterior dominant involvement is considered to be related to a sparse distribution of symphatetic nerve in the vertebra basilar circulation, in contrast to the anterior

cerebral circulation, which is richly innervated by sympathetic nerve.¹² Several proposed mechanisms include disruption of cerebral autoregulation during periods of high blood pressure leading to incompetency of the blood-brain barrier and vasogenic edema; endothelial dysfunction leading to disruption of blood-brain barrier integrity; and focal or diffuse vasospasm seen on catheter angiography. Clinically, symptoms develop acutely over hours and can have a wide range of presentations depending on the area of the brain involved.¹³

The brain perfusion is maintained by autoregulatory system of small artery and arteriola that have myogenic and neurogenic components. Destruction of endothel may attenuate or obviate the myogenic respond.

Perivascular sympathetic nerve, that will protect the brain if myogenic respond does not respond or over respond, founded on adventitial layer of brain's vessels and protected from endothel destroyer agent. Thus the vertebrobasilar system and cerebral posterior artery is rare to be innervated by sympathetic nerve, systemic pressure.^{14,15}

Recently, a research that used USG doppler has shown enhancement of cerebral perfusion pressure and lower resistance of cerebrovascular at patient with eclampsia,¹⁶ the enhancement of blood flow to occipital lobe of the brain at the patient that had SPECT and xenon computed tomography. The seizure more common occurred at the patient with brain edema compared by the normal one. This finding most likely reflects irritation effect of fluid in subcortical and cortical tissue. Some writers has suggested, based on the correlation between general seizure with encephalopathy hypertension, that radiography imaging at the patient with encephalopathy hypertension can be represented by edema seizure.^{17,18}

Computed tomography (CT) scan showed vasogenic edema, particularly at substantia alba parietooccipital subcortical, yet brain stem area, cerebellum, frontal lobe, and ganglia basale could be involved.¹⁹ The new findings on Magnetic Resonance Imaging (MRI) and fluid attenuated inversion recovery (FLAIR) sequences, diffusion-weighted imaging (DWI), and apparent diffusion coefficient (ADC) mapping shown that edema occurred at the both substantia alba and grisea. The etiology of PRES was still unknown, yet the

two main theories that had been proposed about mechanism of the course. One of them had opinion that autoregulation cerebral failure was triggered by hypertension. Autoregulation cerebral failure caused vasodilatation and then enhanced capillary hydrostatic pressure that caused vasogenic edema.²⁰ The involvement of parietal lobe and occipital was considered had a relation with innervation of sympathetic nerve on posterior circulation that relatively bad. One of the syndrome feature was edema without infarction. Thus, introduction and appropriate medication of the syndrome was very important to stop the progressiveness, found and coped the causes and prevented permanent damage or death.²¹

Based on the two theories above, it was important to determine between vasogenic edema and cytotoxic edema, which have different strategy management. It is suggested to divide the PRES patient into two subgroups, patient with hypertension encephalopathy and patient with toxic encephalopathy. On the patient with vasogenic edema, lowered blood pressure and supporting steps was the first line of treatment, while the patient with cytotoxic edema and infark needed more aggressive approach that followed by another etiology, such as subarachnoid bleeding with vasospasm.²⁰

The previous neuroimaging finding reported reversible hypodens CT and hypersensitivity on T2W and FLAIR.⁸ At this case, DWI, included ADC quantification, is the primary imaging modality. This new MR sequence showed the movement of water molecule used 2 metrics, mean diffusivity (MD) and fractional anisotropy (FA), which represented the magnitude and the direction of water. Cytotoxic edema was caused by acute ischemic and infarc, and gradually lower ADC through a reduction of proton diffusibility. The fact above made a brighter sign of DWI and was believed reflected enhancement of intracellular activity and lower extracellular fluid due lower Na⁺ and K⁺-ATPase. Yet, on DWI, vasogenic edema can be looked as enhancement intensity sign (T2 shine-through effect)^{22,23}.

The change of MRI of PRES had proved occur on an area that passed by posterior circulation and disorder of anterior circulation occurred on severe case. It could be caused by inadequate innervation of sympathetic nerve on vertebrobasilar artery posterior cerebral rather than cerebral anterior vessel.^{24,25}

The management combined symptomatic life-supporting treatments and control of the factor causing PRES. Efforts were made to control systemic secondary brain insults and to limit effects of potential cranial hypertension hypoglycemia was routinely checked and corrected. If glucose was given, 100 mg of thiamine was administered concomitantly, most notably when there was evidence of vitamin B1 deficiency. Patients were also routinely evaluated for hyperthermia, hyperglycemia, hypo- or hypercarbia, anemia, metabolic disturbances, epileptic activity and aspiration pneumonia that may complicate the initial consciousness disorders and which required prompt correction. Patients with status epilepticus were managed as previously described. Control of severe hypertension, if present, was an important part of the symptomatic management. Intravenous antihypertensive drugs including labetalol, nicardipine, or urapidil were given.⁷

Posterior syndrome encephalopathy reversible needs an immediate therapy, a delay might caused permanent brain damage. The PRES therapy involve lowering blood pressure, relieving the predisposition agent, and using of anticonvulsan drug on patient with seizure. The seizure usually discontinue after the treatment and doesn't need further antiepileptic drugs.²⁶

CONCLUSION

The pathophysiology of PRES on patient with eclampsia are not fully known. It was believed came from vasculopathy of posterior circulation caused by lower autoregulation adrenergic and enhanced by endothelial cell damage. MRI is the best choice of modality, not only to eliminate the differential diagnosis, like encephalitis, thrombosis sinus, and brain ischemic, but DWI and particularly ADC quantification, for furthemore can differ vasogenic edema and cytotoxic edema. It was important to differ encephalopathy hypertension and toxic encephalopathy, particularly on the patient that showed specific symptoms such headache, seizure, visual deficit, and change of mental status, immediate treatment is needed to maximize potential of reversibility.

REFERENCES

1. Hong S, Jung JM, Ryu HJ, Kwon DY, Park MH. Posterior Reversible Encephalopathy Syndrome Following Rapid Correction of

- Anemia. *Depart of Neuro & Dermato*; 2013. 18(4) : 423.
2. Doelken, M., Lanz S., Rennert J., Alibek S., Richter G., Doerfler A. Differentiation of cytotoxic and vasogenic edema in a patient with reversible posterior leukoencephalopathy syndrome using diffusion-weighted MRI. *Diagn Interv Radiol*; 13. 2007:125-128.
3. Lamy, C., Oppenheim C., Meder J.F., Mas J.L. Neuroimaging in posterior reversible encephalopathy syndrome. *J Neuroimaging*; 14. 2004:89–96.
4. Bartynski, W.S., Boardman J.F. Catheter angiography, MR angiography, and MR perfusion in posterior reversible encephalopathy syndrome. *Am J Neuroradiol*;29. 2008:447-455.
5. Hedna VS, Stead LG, Bidari S, Patel A, Gottipati A, Favilla CG. Posterior reversible encephalopathy syndrome (PRES) and CT perfusion changes. *Int Journ of Emergency Med*; 2012.5(12):1-3.
6. Graham BR, Pylypchuk GB. Posterior reversible encephalopathy syndrome in an adult patient undergoing peritoneal dialysis: a case report and literature review. *BMC Nephrology*; 2014.15(10):1-3.
7. Legriel S, Schraub o , Azoulay E, Hantson P, Magalhaes E, Coquet I. Determinants of Recovery from Severe Posterior Reversible Encephalopathy Syndrome. *Medical-Surgical Intensive Care Department*; 2012.7(9): 4.
8. Hinchey, J., Chaves C., Appignani B.. A reversible posterior leukoencephalopathy syndrome. *N Engl J Med*; 1996.334:494–500.
9. Donaldson, J.O. Eclamptic hypertensive encephalopathy. *Semin Neurol*; 1988. 8(3):230–233.
10. Schwartz, R.B., Feske S.K., Polak J.F. Preeclampsia-eclampsia: clinical and neuroradiographic correlates and insights into the pathogenesis of hypertensive encephalopathy. *Radiology*; 2000.217(2):371–376.
11. Sheth, R.D., Riggs J.E., Bodenstienier J.B., Gutierrez A.R., Ketonen L.M., Ortiz O.A. Parietal occipital edema in hypertensive encephalopathy: a pathogenic mechanism. *Eur Neurol*; 1996.36(1):25–28.
12. Hata M, Oishi A, Kurimoto Y, Yamamoto S, Kohara N. A Case of Posterior Reversible

- Encephalopathy Syndrome Presenting With Isolated Diplopia. *J Vlinic Experiment Ophtalmo*; 2011.2(5):2.
13. Cai X, Bhattacharyya S, Plitt A, Raibagkar P, LaBuzetta ZN, Schleicher SM. Management of Posterior Reversible Encephalopathy Syndrome Induced by Carfilzomib in a Patient With Multiple Myeloma. *Journ of Clinical Onco*; 2014.32:4.
 14. Kaskel, F.J., Deverajan P., Birzgalis A., Moore L.C. Inhibition of myogenic autoregulation in cyclosporine nephrotoxicity in the rat. *Ren Physiol Biochem*; 1989.12:250-259.
 15. Williams, K.P., Wilson S. Persistence of cerebral hemodynamic changes in patients with eclampsia: a report of three cases. *Am J Obstet Gynecol*; 1999.181:1162–1165.
 16. Ohnom, Y., Wakahara Y., Kawai M., Arii Y. Cerebral hyperperfusion in patient with eclampsia. *Acta Obstet Gynecol Scand*; 1999.78:555–556.
 17. Yaffe, K., Ferriero D., Barkovich A.J., Rowley H. Reversible MRI abnormalities following Seizures. *Neurology*; 1995.45:104–108.
 18. Puppala, S., & Hourihan, M.D. A pressing case of transient blindness. *British J of Radiol*, 2005.78, 967-968.
 19. Javad, M.A., Hussain-Sial, M.S.H., Lingawi, S., Alfi, A., Lubbad, E. Etiology of posterior reversible encephalopathy syndrome. *Pakistan Journal of Medical Sciences Quarterly*; 2005. 21(2), 149-154.
 20. Schneider, J.P., Krohmer S., Gunther A., Zimmer C. Cerebral lesions in acute arterial hypertension: the characteristic MRI in hypertensive encephalopathy. *Rofo*; 2006.178:618–626.
 21. Brubaker, L.M., Smith J.K., Lee Y.Z., Lin W., Castillo M. Hemodynamics and permeability changes in posterior reversible encephalopathy syndrome measured by dynamic susceptibility perfusion weighted MR imaging. *Am J Neuroradiol*, 26, 2005.825-830.
 22. Gray, L., MacFall J. Overview of diffusion imaging. *Magn Reson Imaging Clin N Am*; 1998.6:125–138.
 23. Covarrubias, D.J., Luetmer P.H., Campeau N.G. Posterior reversible encephalopathy syndrome: prognostic utility of quantitative diffusion-weighted MR images. *AJNR Am J Neuroradiol*; 2002.23:1038–1048.
 24. Garg, R.K. Posterior leukoencephalopathy syndrome. *Postgrad Med J*; 2001.77:24–28.
 25. Casey, S.O., Sampaio R.C., Michel E., Truwit C.L. Posterior reversible encephalopathy syndrome: utility of fluid-attenuated inversion recovery MR imaging in the detection of cortical and subcortical lesions. *Am J Neuroradiol*; 2000.21:1199–1206.
 26. Stott, V.L., Hurrell M.A., Anderson TJ. Reversible posterior leukoencephalopathy syndrome: a misnomer reviewed. *Intern Med J*; 2005. 35:83–89.